

Revision rhinoplasty: review of deformities, aetiology and treatment strategies

H. D. VUYK, S. J. WATTS* & B. VINDAYAK†

*Department of Otolaryngology, Plastic Surgery, Gooi Noord Hospital, Blaricum, The Netherlands, *European Academy of Facial Plastic Surgery Fellow and †Department of Otolaryngology, Facial Plastic Surgery, Royal Berkshire Infirmary, Reading,*

Accepted for publication 14 December 1999

VUYK H.D., WATTS S.J. & VINDAYAK B.
(2000) *Clin. Otolaryngol.* 25, 476-481

Revision rhinoplasty: review of deformities, aetiology and treatment strategies

Rhinoplasty has always been one of the most challenging aspects of facial surgery as it requires a precise assessment of the deformity, a strong grasp of nasal support mechanisms plus soft tissue skin envelope and a realistic appraisal of the outcome expected acutely and over a long period of time. This fine balance is often achieved by retrospective analysis of post-rhinoplasty results in order to highlight repeated problems and improve upon them. This study reviews 110 patients in which a total of 407 deformities were found. These are divided into upper, middle and lower thirds with a subdivision of individual deformities within each group. There is also a comparison of the results obtained from similar studies over a period of four decades to those in our study, which reveals that the post-rhinoplasty deformities noted in these studies occur with a similar frequency to those in our paper.

Keywords *revision rhinoplasty deformities*

The therapeutic challenge of revision rhinoplasty is undeniable. Generally, each subsequent rhinoplasty becomes increasingly difficult, rendering perfection an illusionary goal.¹ Possible difficulties envisaged in this area stress the need for accurate analysis of their individual deficiencies and the need for thoughtful psychosocial management of the patient.²

Post-rhinoplasty deformities vary enormously but it is possible that a pattern of deformities can be distinguished and a systematic retrospective analysis of 110 consecutive revision rhinoplasty patients was used to investigate this pattern.

In order to conceptualise this recurrent pattern, we will concentrate on the possible aetiology of these problems and a subsequent management strategy is suggested for prevention and treatment of post-rhinoplasty deformities.

Methods and patients

During a 5-year period, a total of 480 rhinoplasties were performed by the first author at the Gooi Noord Hospital.

Correspondence: Dr H. D. Vuyk, Department of Otolaryngology, Facial Plastic Surgery, Gooi Noord Hospital, Rijksslraat 1, 1261 A N Blaricum, The Netherlands.

Of these 110 (23%) had already had at least one previous rhinoplasty and it is this subgroup that is the focus of this paper.

Of the 110 patients, 44 were men and 66 women with a mean age of 36 years (range 20-69 years). The mean number of rhinoplasties per patient was 1.5, with 68 patients (62%) having undergone one previous procedure and the remainder (38%) between two and four.

The primary surgery in this population group was performed using the endonasal approach in 93% of patients. Ten (9%) of the 110 patients had their primary surgery performed at Gooi Noord Hospital with the majority of referrals from other centres.

A residual or iatrogenic aesthetic deformity was the main indication for surgery with approximately two-thirds of patients having additional functional nasal problems also addressed at the time of surgery.

Analysis of the standardized preoperative slides included six views: frontal, basal, left and right lateral plus three-quarter views. The nose was divided into thirds (Fig. 1) with each area studied individually. Specific deformities were noted in the upper third (bony pyramid), middle third (cartilaginous pyramid) and the lower third (tip, ala, columella).

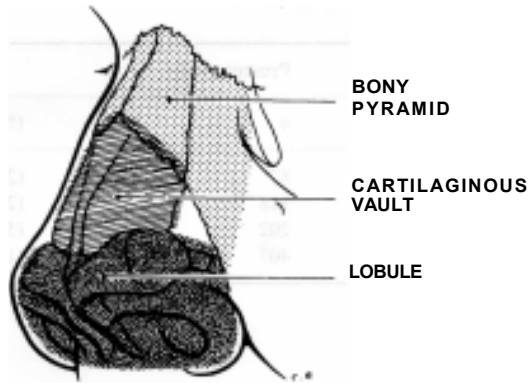


Figure 1. Nasal architecture denoting the divisions into upper, middle and lower thirds.

Results

In the 110 patients studied, a total of 407 deformities were identified with the mean number of deformities per patient of 3.7 (range 1-9). Tables 1 and 2 show the number of deformities subdivided into their various locations. The most frequently encountered aesthetic deformities encountered are detailed in Table 3.

Discussion

The basic interest in post-rhinoplasty deformities is fuelled by the urge to prevent them and, in order to do this, we must define and understand our failures. In this regard, data accumulated from previous studies is helpful to support or reject our notions.

Adamson⁴ categorized revision rhinoplasty patients according to the number of deformities present. In his study

Table 2. Aesthetic deformities of the lower third

Tip		
Position		
Over Projected		5
Under projected		36
Over rotated		7
Under rotated		19
Deviation		1
Shape		
Broad		20
Amorphous		18
Narrow		6
Asymmetry		33
External scar		5
Columella		
Hanging		7
Retracted		12
Sharp nasolabial angle		18
Subluxation		1
Ala		
Retracted		8
Broad alar base		6
Total		202

50% of the patients had one deformity, 30% two deformities and 20% three or more deformities. However, in our study 80% of the patients had two or more deformities although this relatively high figure may be explained by the fact that a wider range of deficiencies was included in our study.

With regard to the location of the deformities, a number of studies indicate the lower third to be the site where the greatest number of deformities are found followed by the middle third.^{5,6} Only one study mentioned the middle third and more specifically a 'pollybeak'¹ deformity as the most frequent cause of revision⁷. Parkes⁸ studied 324 patients

Table 1. Aesthetic deformities of the upper and middle thirds

	Upper 1/3	Middle 1/3
Profile		
High	21	44
Low	36	23
Width		
Broad	14	5
Narrow	4	23
Shape		
Asymmetry	7	16
Irregularity	2	2
Position		
Deviation	3	4
Total	87	118

Table 3. Common presentations of aesthetic deformities per nasal subunit

Location	Deformities
Bony pyramid	Low
	Broad
Cartilaginous pyramid	High
	Narrow
Nasal tip	Under projected
	Under rotated
	Broad
	Amorphous
Columella	Asymmetric
	Retracted
Ala	Retracted

Table 4. Inter-study comparison of upper, middle and lower third deformities

	Parks et al. (1992) ⁸		Present study	
	n	(%)	n	(%)
Upper third	81	(24)	87	(21)
Middle third	111	(32)	118	(29)
Lower third	150	(44)	202	(50)
Total	324	(100)	407	(100)

using a nasal subdivision into thirds similar to our study and the frequency of deformities found in each area was also strikingly similar (Table 4).

In a review of 126 revision cases, Kamer⁷ arbitrarily divided post-rhinoplasty deformities into major and minor. The categories in our study that matched the criteria for the major deformities in Kamer's article were isolated: these included pollybeak formation, saddling, middle nasal asymmetry and columellar retraction. The results of each study were compared and again showed similarities between the two studies as shown in Table 5.

In reviewing the literature including the results from our study, a repetitive pattern of deformities becomes apparent (Fig.2).

Profile photographs of two revision rhinoplasty candidates illustrate this typical deformity pattern with Fig. 3(a) showing a patient with thick nasal skin and Fig. 3(b) showing a patient with thin nasal skin.

It is important to note that our study, and the majority of the studies mentioned above, are between one and four decades apart, showing a repeated inherent difficulty in understanding and preventing these problems.

These problems will be further discussed below with various management solutions proposed.

AETIOLOGY OF DEFORMITIES

Having defined the most frequently encountered deformities, the next step towards their prevention is the conceptua-

Table 5. A comparison of results shown by Kamer and the present study

	Kamer (1988)	Present study
Pollybeak	56%	40%
Saddling	16%	21%
Midnasal asymmetry	19%	14.5%
Retracted columella	9%	11%

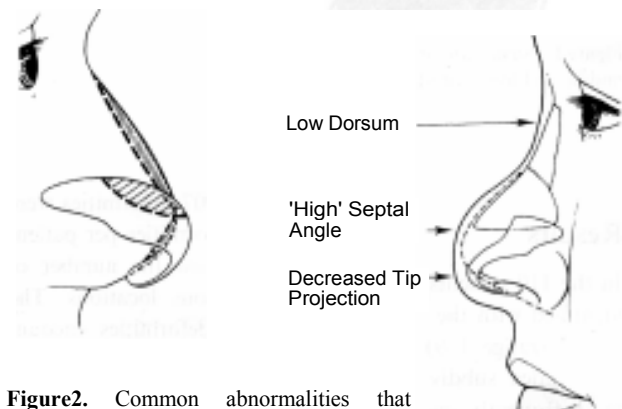


Figure2. Common abnormalities that present post rhinoplasty are those of a low dorsum with a 'pollybeak' deformity induced by a relatively high septal angle combined with decreased tip projection.

lization of their aetiology in the post-rhinoplasty patterns. Referring to Table 3 it is apparent that the most frequent deformity found in the upper third was a low and broad bony pyramid and this is portrayed in the A-P views as an indistinct separation of the eyes with a 'washed out' appearance. In most cases this is the result of over resection of the bony hump leaving the nasal bones in an outward oblique position. In many patients it is the result of a failure to perform osteotomies or an inadequate in-fracture after incomplete osteotomies. This problem will, in turn, manifest more frequently if a chisel or osteotome is used rather than a rasp or burr which allows a more incremental reduction.¹

The commonest deformities encountered in the middle third were a high profile and narrow nose. A relatively high cartilaginous middle third occurs mainly as a result of under-resection of the anterior septal angle with an unanticipated loss of tip projection (see below) accentuating this deformity.

Narrowing of the middle third may also occur after merely separating the Iriangular cartilages ofT the dorsal septal edge, causing a medialization of the lateral nasal wall.

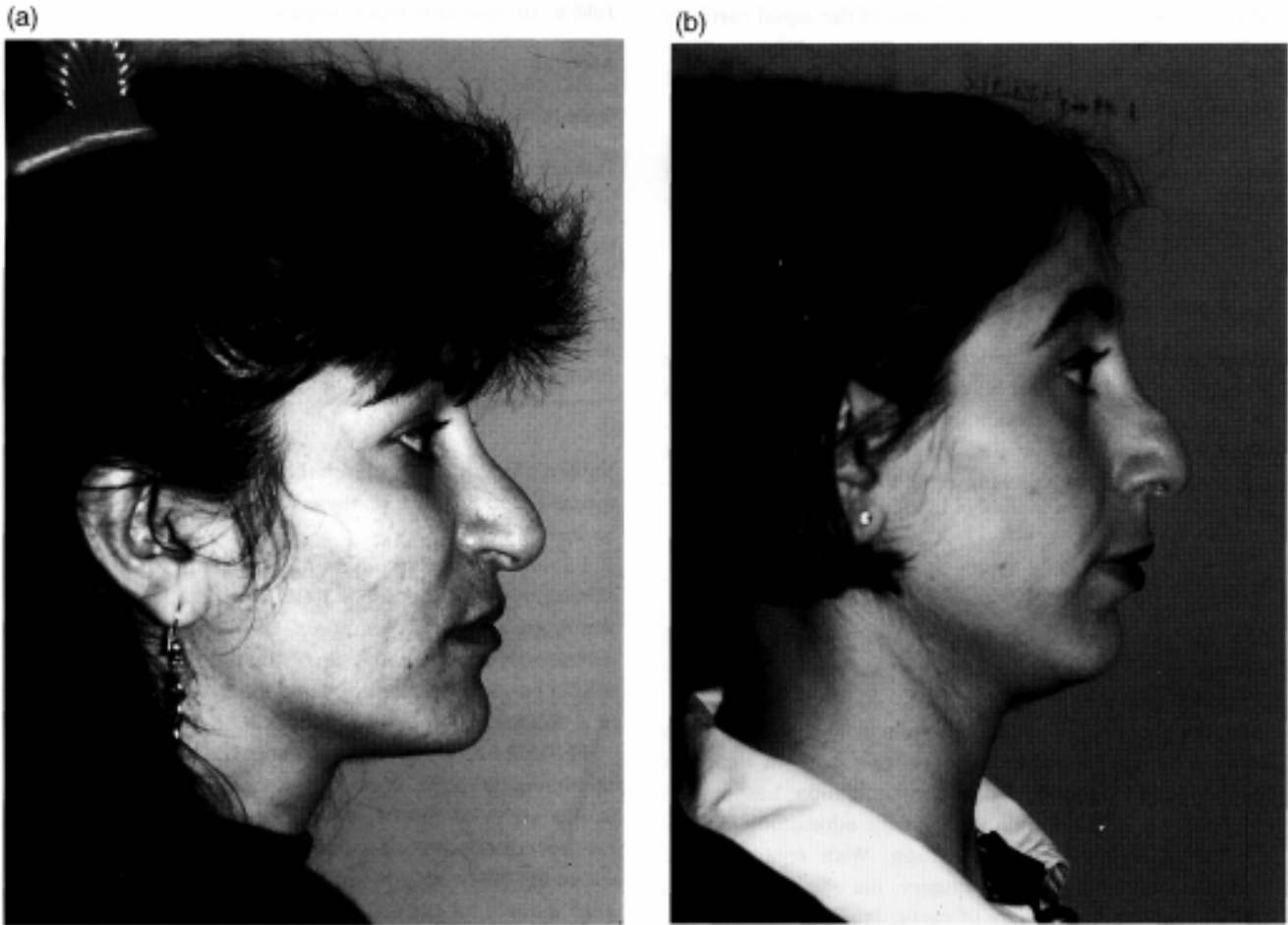


Figure 3. (a): A 'pollybeak' deformity in a patient with thick skin. (b): A 'pollybeak' deformity in a patient with thin skin.

If the middle third profile is lowered and the triangular cartilage with dorsal edges resected, the normal T-shaped structure of the cartilaginous dorsum is lost and converted to an I-shape, further increasing the risk of a poor aesthetic result.⁹ This 'pinched' appearance may be a telltale sign of a functional problem caused by collapse in the region of the nasal valve.

The most common abnormality in the lower nasal third in terms of nasal tip position is under projection and under rotation. This is caused by disruption of one or more of the three important tip support mechanisms, namely the attachment of the medial crura to the nasal septum, the shape and resilience of the alar cartilages and the attachment of the alar cartilages to the upper lateral cartilages.¹⁰

A combination of transiixion and intercartilaginous incisions as well as volume reduction of the alar cartilages without augmentation has been shown to reduce nasal tip projection in the vast majority of patients." This loss of tip projection may be immediately obvious or it may be a delayed phenomenon as intraoperative assessment can be

difficult. Swelling of the tip region due to local anaesthetic infiltration and intraoperative swelling plays a major part¹² as does the use of intranasal retractors in the endonasal approach obscuring the true position of the tip.

Further loss of tip projection from resolution of tissue oedema and scar contracture should be anticipated during a postoperative period of up to 1-2 years.

Evaluation of nasal tip shape showed a broad amorphous tip and asymmetry to be common occurrences. Directly related to the loss of tip projection, the domal angles widen, changing the tip from pointed to a wider, blunted trapezoid shape. Subsequently the skin soft tissues need to adapt to a smaller nasal tip cartilage skeleton, leading to skin thickening and blunting (Fig. 3a). Scar formation, particularly after traumatic dissection of the soft tissue envelope off the nasal skeleton may further compound the problem.

In the alar and columella region, retraction was a relatively common finding. This may result from scar tissue formation, which debilms already weakened or partially resected alar cartilages.¹³ Columella retraction may result

from over resection of the caudal end of the septal cartilage and/or the nasal spine while caudal rotation of the cartilaginous septum following over mobilization and/or vertical shortening has also been referred to as a possible cause.¹⁴

Generally, irregularities occur through inadequate bony or cartilaginous resection but traumatic, uneven dissection of the soft tissue envelope will also result in a similarly poor outcome.

MANAGEMENT STRATEGIES

The concept of problem aetiology may be the basis for the formulation of a surgical management strategy, which can be applied for both prevention and treatment. However, surgical expertise aside, detailed preoperative assessment and realistic patient expectations will determine patient outcomes.²³

PREOPERATIVE MANAGEMENT

The preoperative consultation should include a careful assessment of patient suitability, psychological characteristics and motivation.

A frank discussion of limitations and likely outcome as well as possible complications are obligatory in order to gain informed consent. Computer simulation has proved helpful for communication and patient education¹⁵ as has the use of documented information. With regard to the technical details of previous surgery, the approach used as well as implants inserted are of particular interest.

Relying on a detailed checklist, analysis of deformities in the upper, middle and lower thirds is undertaken.¹⁶ The proposed operation is then planned in detail whilst taking into account the complex interrelationships of the nasal structures. Standardized preoperative photographs are considered obligatory to help with planning and form a necessary part of legal documentation.¹⁷

SURGICAL STRATEGY

We use the open approach in over 90% of our patients presenting for both primary and revision surgery. In the few cases that require the creation of small pockets for localized augmentation, the endonasal approach is used.

Other authors¹⁸⁻²⁰ have written about the benefits of the open approach in revision rhinoplasty as it allows for good exposure and precise diagnosis, while facilitating excellent access for corrective procedures. Generally, the incidence of problems such as poor wound healing, wound dehiscence and columella skin flap necrosis is extremely rare with none reported in this series. The same holds true for unacceptable scarring which is also minimal in most series evaluated.²¹

The reconstructive procedures employed to reshape the bony-cartilaginous pyramid in this series are summarized in

Table 6. Revision rhinoplasty: surgical strategies

Approach	Percentage
Open	93%
Closed	7%
Technique	
Columella strut	65%
Tip graft	60%
Dorsal augmentation	50%
Suture repositioning of alar cartilage	40%
Spreader graft	30%
Lat. wall augmentation	25%
Alar augmentation	15%
Premaxilla augmentation	15%

Table 6. As this paper places the emphasis on aetiology and diagnosis, only some of these restructuring techniques will be highlighted.

To reinforce and maintain nasal tip support we rely on a cartilaginous strut, which is fixed to the medial crura and/or the nasal spine.²¹ A variation of the latter technique is increasingly applied today involving the repositioning of the medial crura in relation to the cartilaginous septal extension in a 'tongue and groove' like fashion.'

The deformity and the subsequent surgical goals dictate the shape and position of cartilaginous tip grafts. As shown in our series of results, if an increase in tip projection is needed, we rely on autogenous tip grafts.²⁴ To this end we either use an onlay graft in the domal region, a shield type graft sutured to the infra-tip lobule (rarely) or a combination of both.^{25,26} These grafts should be appropriately bevelled to soften the edges enabling moulding into the alar cartilage complex. This is particularly relevant in thin-skinned patients in order to prevent the graft showing after long-term follow-up. To prevent this problem, additional perichondrium or temporalis fascia onlay grafts will help to soften any visible edges.

Total nasal dorsal augmentation taxes the surgeon's ingenuity with regard to technique and choice of materials used²⁷ although autogenous grafts remain the materials of choice. Whether alloplasts like Gore-tex^R are used for total augmentation of the nasal dorsum in revision rhinoplasty is still subject to further investigation. Strong arguments for the use of autogenous materials and against alloplasts are thin skin, a scarred recipient site, direct contact with the nasal cavity and septal perforation repair.²⁸ It should be noted, however, that the premaxillary area might be a region where alloplasts are accepted as the covering soft tissues are thick and relatively immobile.

Alar cartilage repositioning using suture techniques has proven predictable and reliable particularly because the changes induced are incrementally applied and reversible, specifically controlling nasal tip positioning and contour.^{21,29-31}