

The inferior turbinate flap for closure of septal perforations

H. D. VUYK AND R. J. J. VERSLUIS

Department of Otorhinolaryngology and Head and Neck Surgery, Academic Hospital of the Free University, Amsterdam

Accepted for publication 18 March 1987

VUYK H. D. & VERSLUIS R. J. J. (1988) *Clin. OtolaryngoL* 13, 53-57 **The**

inferior turbinate flap for closure of septal perforations

In 31 patients a symptomatic septal perforation was repaired using an inferior-turbinate flap originally described by Masing.¹ In approximately 50% of the cases the perforation was closed for two-thirds or more. Postoperative scarring causing nasal obstruction or alar asymmetry occurred in 21% of the cases. Some specific symptoms such as epistaxis, whistling and frontal headache appeared to improve even after partial closure. However, the overall degree of satisfaction of the patients and the degree of closure of the perforation were related. Based on the results of this series the inferior-turbinate flap did not prove satisfactory for the closure of septal perforations.

Keywords *septum perforation turbinate flap*

Perforations of the nasal septum, particularly those located anteriorly, may cause troublesome symptoms such as crusting, obstruction, bleeding and whistling. Long-term symptomatic therapy with ointments and irrigation yields only limited success, similarly silastic buttons only benefit a few patients. For surgical closure several methods have been described in the literature.²⁻⁵ In 1980 Masing introduced the inferior-turbinate flap for closure of septal perforations,¹ and reported an encouraging success rate of approximately 80%. The object of this paper is to present our experience with this flap.

Masing's concept is based on the assumption that most of the symptoms mentioned above are caused by the desiccating effects of the inspiratory airflow on the posterior rim of the perforation. Consequently his surgical technique aims at the protection of the posterior rim of the perforation from the inspiratory airflow

and not necessarily at complete closure of the perforation itself. This surgical technique essentially consists of 2 phases (Figure 1). In the first phase of the procedure a flap of the lateral nasal wall which is centered around the inferior turbinate and includes vestibular skin, is raised and is sutured anteriorly to the anterior, inferior and superior edge of the septal perforation (Figure 2, 3). In the second phase the pedicle of the flap is sectioned posteriorly, rotated into the perforation and sutured in place to the posterior rim to close the defect. According to Masing one-third of the patients are symptom-free after the first stage and have no nasal obstruction. Thus only two-thirds of the patients would need the second stage of the procedure.

Some variations may be applied. For a better exposure lateral alotomy may be performed. A small anterior-superior based septal rotation flap may be used to cover

Correspondence: H.D. Vuyk MD PhD, Department of Otolaryngology, Free University Hospital, de Boelelaan 1117, 1081 H V Amsterdam, The Netherlands.

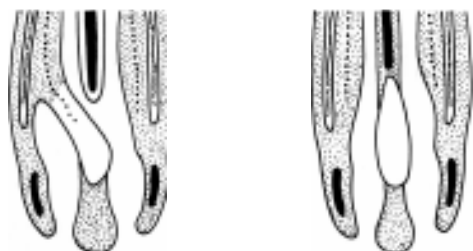


Figure 1. The 2-stage (*a* and *b*) principle of closure of a nasal septal perforation with an inferior-turbinate flap is shown.

the anterior part of the inferior-turbinate flap in the first stage. The mucosal defect on the lateral nasal wall may be covered with a full thickness graft from the retro-auricular skin. Fibrin glue is helpful in fixing the flap and its eventual covering.

This technique has the added advantage of not disturbing the blood supply of the cartilages of the nose. The drawback of course is the 2 stages needed in most patients.

Patiënt material

During a period of 4¹ years, from January 1982 till July 1986, the inferior-turbinate flap has been used in 35 patients. In the same period another 5 patients have been treated surgically for a septal perforation with other techniques. Of the 35 patients, 4 patients were lost to follow-up. Of the remaining 31 patients, 16 were female and 15 male. They varied in age from 19 to 58 years, the average age being 37 years. The mean follow-up at that time of reporting is 16 months, varying from 3 to 39 months. The known causes of the perforations as well as the complaints of the patients have been summarized in Tables 1 and 2. Ten patients had been previously treated elsewhere, with different surgical techniques. Four of these 10 patients had been operated upon more than once. In 4 of the total of 10 surgically treated patients a prosthesis had been applied unsuccessfully.

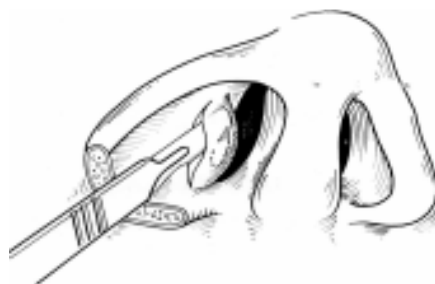

Figure 2. Development of an inferior-turbinate flap. Alotomy is outlined for demonstration purposes. Reprinted with permission from *Laryngologie, Rhinologie und Otologie*, 1980, 59, 50-60.

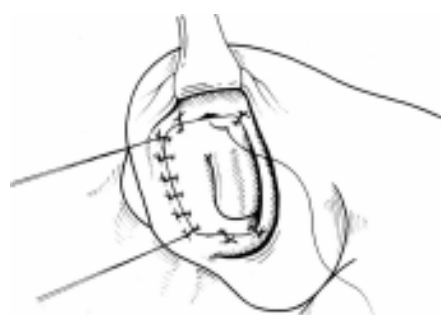

Figure 3. Inferior-turbinate flap is sutured to the mucosa on the opposite site of the septum anteriorly, inferiorly and superiorly. Division of the pedicle of the flap posteriorly requires a second stage. Reprinted with permission from *Laryngologie, Rhinologie und Otologie*, 1980, 59, 50-60.

Another 7 patients had been treated before with a prosthesis only.

The patients were classified according to the diameter and location of the septal perforation. In 2 patients the perforation diameter was less than 0.5 cm. In 21 patients the perforation measured between 0.5 and 1.5 cm, and 8 patients had a perforation with a diameter larger than

Table 1. Causes of nasal septal perforations in 31 patients treated with an inferior-turbinate flap.

Cause	Number of patients
Previous nasal surgery	19*
External trauma	4†
Picking	4
Repeated cautery	1
Undetermined	3

*Four patients had nasal surgery more than once.

†Concomittant infection in 3 patients.

1.5 cm. The anterior margin of the perforation was localized in the vestibular or nasal valve area in 27 patients and at the level of the anterior border of the inferior turbinate in 4 patients. Apart from the symptomatic anterior located perforation, 2 patients had a second perforation more posteriorly which did not need treatment.

Methods

The surgical technique of Masing which has been applied in 31 patients, has been described above. Variations used in the first stage include a lateral alotomy in 15 patients, an anterior mucosal flap in 10 patients, a retro-auricular full thickness graft in 11 patients, while fibrin glue was used in 13 patients. In 1 patient a concomitant septal correction for a posterior deviation was performed.

The inferior-turbinate flap has been successfully transplanted into the anterior part of the perforation in 24 of 31 patients. In 2 of the 7 patients in whom the inferior-turbinate flap failed to take, an inferior-turbinate flap was used from the other side to close the anterior part of the perforation successfully. A success rate of approximately 80% was observed at the first transfer of the flap, i.e. in 26 of the 33 inferior-turbinate flaps used. All of the 26 patients with a successful first transfer of the flap needed the second stage of the procedure. The variations used at this point include a lateral alotomy in 5 patients. In 2 patients, both having a perforation larger than 1.5 cm, the inferior-

turbinate flap was enhanced more posteriorly, thus it was possible to suture the posterior part of the flap in the superior and inferior margins without the pedicle of the flap being divided at this stage. These 2 patients underwent another operative procedure to divide the pedicle completely and close the posterior part of the perforation. In 1 patient a mucosal flap from the floor of the nose was used concomitantly to close the remaining defect. In another patient a submucosal septal correction was performed for a posterior deviation. In only 1 patient was fibrin glue used in the second stage.

Silastic sheets were used to prevent adhesions with the lateral nasal wall in all patients, for a period varying from 1 to 4 weeks postoperatively. Unfortunately in 8 of these 26 patients adhesions developed in the postoperative period causing nasal obstruction. Thus a third procedure was needed in a total of 10 patients, either to divide the remaining pedicle of the flap or to divide the adhesions which developed postoperatively. In 3 of these 10 patients, adhesions occurred again, and a fourth procedure was necessary before successful completion of the treatment.

Results

Data were collected from follow-up examination and a questionnaire filled in by patients. In a total of 31 patients in whom the Masing technique was used, a total of 71 operative procedures have been performed. The results regarding closure of the perforation have been summarized in Table 3. In 18 patients the perforation was closed for two-thirds or more. The first stage of the procedure was unsuccessful in 7 patients. In 3 patients a complete atrophy of the inferior-turbinate flap occurred after division of the pedicle, transposition and suturing to the posterior margin. Although closure of a small perforation seems to present less technical problems than closure of a large perforation, the results

Table 2. Preoperative symptoms in patients treated with an inferior-turbinate flap for nasal septal perforation.

<i>Symptoms</i>	<i>Number of patients</i>
Crusting	26
Epistaxis	18
Nasal obstruction	18
Headache	15*
Whistling	14
Rhinorrhoea	10

*Occipital in 3 patients.

Table 3. Results of surgical closure of nasal septal perforations using 33 inferior-turbinate flaps in 31 patients

Results	Number of patients
Perforation closed—complete	10 (30.3%)
Perforation closed—two-thirds	8 (25.2%)
Perforation closed—one-third	5 (15.2%)
Perforation not closed (failure)	10*(30.3%)

* Seven inferior-turbinate flaps failed to take in the first stage; in 2 cases a second inferior-turbinate flap was used.

Three inferior-turbinate flaps atrophied after division of the pedicle in the second stage.

were not statistically correlated to the size of the treated nasal septal perforation (Chi-square test: $P > 0.05$).

A few other complications occurred. In 4 patients the inferior-turbinate flap was considerably thicker than the septum but not sufficient to cause nasal obstruction. Five patients developed a stenosis of the right nasal passage caused by adhesions and wound retraction, reducing the diameter of the nasal passage to about one-third, but this did not produce any symptoms in 4 of the 5 subjects. In 2 patients, however, stenosis involved two-thirds of the nasal passage causing severe unilateral obstruction of that side. The ala was affected by the surgical procedure in 5 patients. In 1 patient only the sensibility of the nasal ala was altered. In 4 patients the free margin of the right ala was retracted cranially causing asymmetry.

The question is whether the variations of the surgical technique did influence the results and possibly did cause any of the complications. The primary take rate of the inferior-turbinate flap did not show any correlation to a better exposure with alotomy, the use of an anterior mucosal

Table 4. Therapeutic results in 23 patients in whom a partial or total closure of the nasal septal perforation has been obtained using the inferior-turbinate flap

Therapeutic results	Number of patients
Excellent	0
Good	12
Satisfactory	5
Moderate	3
Poor	3

flap or to the use of fibrin glue (Fisher's test: $P > 0.05$). Postoperative scarring with vestibular stenosis or retraction of the alar rim was not related statistically to lateral alotomy, the use of a retroauricular skin graft, fibrin glue or the period of time silastic sheets were used postoperatively (Fisher's test: $P > 0.05$).

The therapeutic results are summarized in Table 4. Only those patients in whom the perforation was partly or totally closed were asked to fill in the questionnaire. Seventeen of the 23 patients or almost 75% rated the results of the combined procedures as satisfactory or good. A statistical correlation was found between the degree of satisfaction of the patients and the degree of closure of the septal perforation obtained after the surgical treatment (Chi-square test: $P < 0.05$). Moreover, the patients were asked whether their specific symptoms had been improved, remained the same or were considered worse after the procedures (see Table 5). In most of the patients symptoms of epistaxis, whistling sounds and frontal headache improved. Crusting and rhinorrhoea improved in some. However, nasal obstruction improved in 7 patients, remained the same in 8 but increased in 4 patients. The deterioration was caused by vestibular stenoses in 2 patients and excessive crusting in the 2 other patients.

Comment

As the number of patients in whom the inferior-turbinate flap was used for closure

Table 5. Therapeutic results relative to specific symptoms after partial or total closure of nasal septal perforation using the inferior turbinate flap

Symptoms	Better	Unchanged	Worse
Crusting	9	10	0
Epistaxis	10	3	0
Nasal obstruction	7	8	4
Whistling	10	1	0
Headache	9	4*	0
Rhinorrhoea	5	4	0

*Including 2 patients with occipital headache.

of their septal perforation has grown, there has been an increasing awareness of the problems and complications associated with this surgical technique.

In approximately 50% of the cases two-thirds or more of the perforation could be closed. Most of the failures occurred in the first stage as the inferior-turbinate flap failed to take in 21% of the cases. After a successful first stage, the second stage of the procedure had to be carried out in every patient, mostly because of nasal obstruction on the side of the flap. Some patients needed more than 2 operations, mostly because of recurring adhesions between the septum and the lateral nasal wall.

Severe complications such as stenosis of the nasal passage causing obstruction and alar-asymmetry were seen in 21% of the cases. We could not establish a relationship between success and complication rate on the one hand and between patient characteristics and technical variations on the other. This implies that neither strict patient selection criteria nor improvement of technical details would improve the results of this method in the future.

It has been our experience that some specific symptoms such as epistaxis, whistling and frontal headache appeared to improve with this technique in most of the cases, even after partial closure. Masing postulated that this was due to the protection of the posterior rim of the

perforation from the desiccating effect of the inspiratory air flow. In half of the patients other symptoms, such as crusting, nasal obstruction and rhinorrhoea did not improve, not even after complete closure. However, it was significant that the overall degree of satisfaction of the patients and the degree of closure of the perforation were related. This did sustain our notion that one has to strive for a complete reconstruction of the septal defect, still knowing that symptoms will remain with some patients.

Based on the results of this series the inferior-turbinate flap did not prove satisfactory for closure of septal perforations. In view of the difficulty of the problem the success rate may be acceptable, but multiple stages are involved and complications may be difficult to treat.

References

- 1 MASING H., GAMMERT CH. & JAUMANN M.P. (1980) Unsere Konzept zur operativen Behandlung vom Septumperforationen. *Laryngol. Rhinol. Otol* **59**, 50-56.
- 2 GOLLOM J. (1968) Perforation of the nasal septum: the reverse flap technique. *Arch. Otolaryngol* **88**, 84-88
- 3 TARDY M.E. (1973) Septal perforations. *Otolaryngol. Clin. N. Am.* **6**, 711-713
- 4 FAIRBANKS D.N.F. (1980) Closure of nasal septal perforations. *Arch. Otolaryngol.* **106**, 509-513
- 5 KARLAN M.S., OSSOF R. & CHRISTU P. (1982) Reconstruction for large septal perforations. *Arch. Otolaryngol.* **108**, 433-436