

# Reconstruction of Nasal Sidewall Defects After Excision of Nonmelanoma Skin Cancer

## *Analysis of Uncovered Subcutaneous Hinge Flaps Allowed to Heal by Secondary Intention*

Paul van der Eerden, MD; Mark Simmons, MA(Oxon), FRCS(ORL-HNS); Hade Vuyk, MD, PhD

**Objective:** To describe the experience of a single department using uncovered subcutaneous hinge flaps to repair the nasal portion and adjacent facial subunits of defects after skin tumor excision.

**Design:** Case series of 16 patients needing reconstruction for lesions of the alar subunit with 1 or more adjacent facial subunits after Mohs surgery for cutaneous malignant neoplasms.

**Results:** All flaps healed well by secondary intention, and the results were gauged at least satisfactory by the patients and surgeons. In 4 patients there were minor aesthetic con-

cerns: in 1 patient the underlying cartilage graft was prominent and a minor revision was undertaken, 1 patient had effacement of the nasofacial sulcus, 1 patient developed a hypertrophic scar, and 1 patient developed both effacement of the nasofacial sulcus and a scar.

**Conclusions:** The use of subcutaneous hinge flaps allowed to heal by secondary intention is a simple 1-stage technique that may be useful in reconstruction of small but deep nasal sidewall defects.

*Arch Facial Plast Surg.* 2008;10(2):131-136

**R**ECONSTRUCTION OF DEFECTS involving the lateral nasal sidewall, medial part of the cheek, nasal alar subunit, and upper lip areas poses particular problems. This area has complex anatomic relationships, with a number of different facial subunits meeting in a small area. Each unit has differing characteristics of contour, soft-tissue thickness, and skin color and texture. There may also be a natural sharp change in contour where these areas meet. If a defect occupies more than 1 of these subunits, it is preferable to reconstruct each area separately so that reconstructive flaps or grafts do not span or disrupt important anatomic and aesthetic landmarks, such as the supra-alar groove, nasofacial sulcus, or melolabial crease. Because of the superficial nature of the nasal cartilages in this region, additional cartilage grafting may be needed to replace any local cartilage resected to ensure tumor margin clearance. In addition, it is always wise to place additional nonanatomic cartilage grafts to support the repair because without these there may be postoperative compromise to the nasal valve area or retraction of the alar rim.<sup>1,2</sup> Cartilage may also be valuable for replacing tissue bulk in deep wounds. This limits the possibilities

of skin grafting because vascularized tissue is required to cover the cartilage.

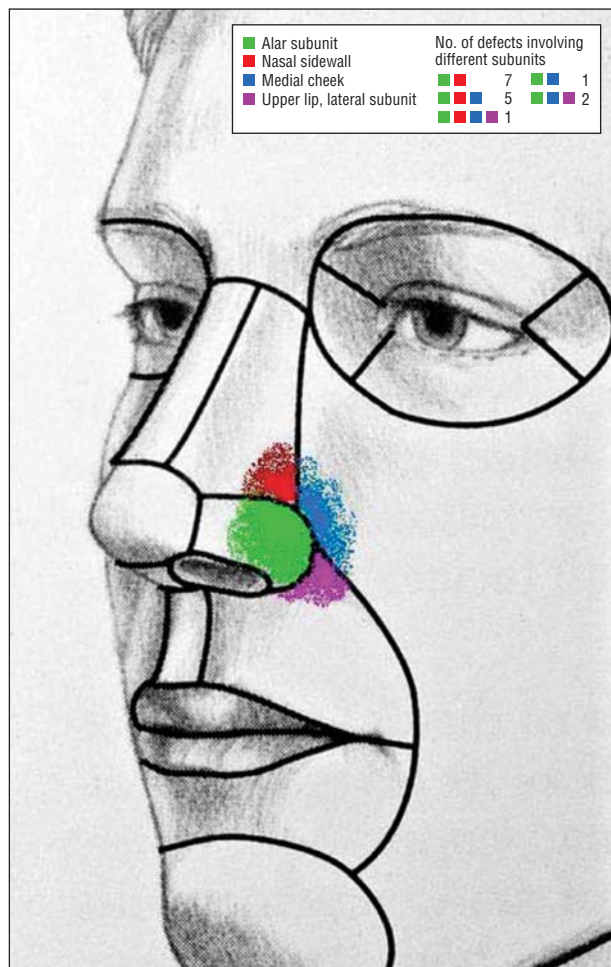
When a single defect encompasses more than one of the anatomic facial subunits, the reconstruction may need to include tissue to fill a small but deep defect of 1 of the subunits. The value of subcutaneous hinge flaps in the reconstruction of the nasal portion of such defects has been described and reviewed by Johnson et al<sup>3</sup> and Baker.<sup>4</sup> They recommended repairing the nasal portion of the defect by using a fat flap (and, if necessary, fat/muscle composite) from the medial part of the cheek. These flaps, which are hinged in the area of the nasofacial sulcus, allow filling of the deep soft-tissue defects often found after Mohs excisions in this region. The technique also allows free conchal cartilage grafting to provide support if necessary. The cheek portion of the defect is then addressed separately with the use of a cheek advancement flap. According to Baker,<sup>4</sup> the skin from the Burow triangles needed to allow the cheek advancement may be used as full-thickness skin grafts to cover the fat flap. In his discussion, Baker suggests that such subcutaneous fat hinge flaps might be amenable to healing by secondary intention should no skin be available to cover them. However, the 2 published

**Author Affiliations:**  
Department of Otolaryngology, Lange Land Hospital, Zoetermeer, the Netherlands (Dr van der Eerden); Department of Otolaryngology, Walsall Manor Hospitals NHS Trust, Walsall, England (Dr Simmons); and Department of Otolaryngology and Facial Plastic Surgery, Gooi-Noord Hospital, Blaricum, the Netherlands (Dr Vuyk).

**Table. Patient and Wound Characteristics<sup>a</sup>**

Patient No./ Sex/Age, y	Tumor	P or R	% of Wound in Each Facial Subunit				Cheek Advancement	Follow-up, mo
			Alar Subunit	Nasal Sidewall	Medial Cheek	Upper Lip, Lateral Subunit		
1/F/49	BCC	P	10	90	0	0	No	24
2/F/49	BCC	P	40	60	0	0	No	5
3/M/54	BCC	R	20	50	30	0	Yes	17
4/M/44	BCC	P	80	0	20	0	No	7
5/M/71	BCC	P	20	80	0	0	Yes	65
6/F/79	BCC	R	10	0	40	50	Yes	12
7/M/54	BCC	P	20	80	0	0	Yes	9
8/M/68	BCC	P	80	20	0	0	No	5
9/F/68	BCC	R	20	70	10	0	Yes	11
10/M/71	BCC	P	25	10	60	5	Yes	5
11/F/79	BCC	P	20	0	50	30	Yes	46
12/F/63	BCC	P	10	80	10	0	No	13
13/F/74	BCC	P	30	70	0	0	Yes	8
14/F/72	BCC	P	30	40	30	0	Yes	9
15/M/74	SCC	R	0	90	10	0	Yes	6
16/F/54	BCC	P	20	80	0	0	No	51

Abbreviations: BCC, basal cell carcinoma; P, primary; R, recurrent; SCC, squamous cell carcinoma.  
<sup>a</sup>All patients underwent autogenous cartilage grafting.



**Figure 1.** Number of defects involving different nasal and facial subunits.

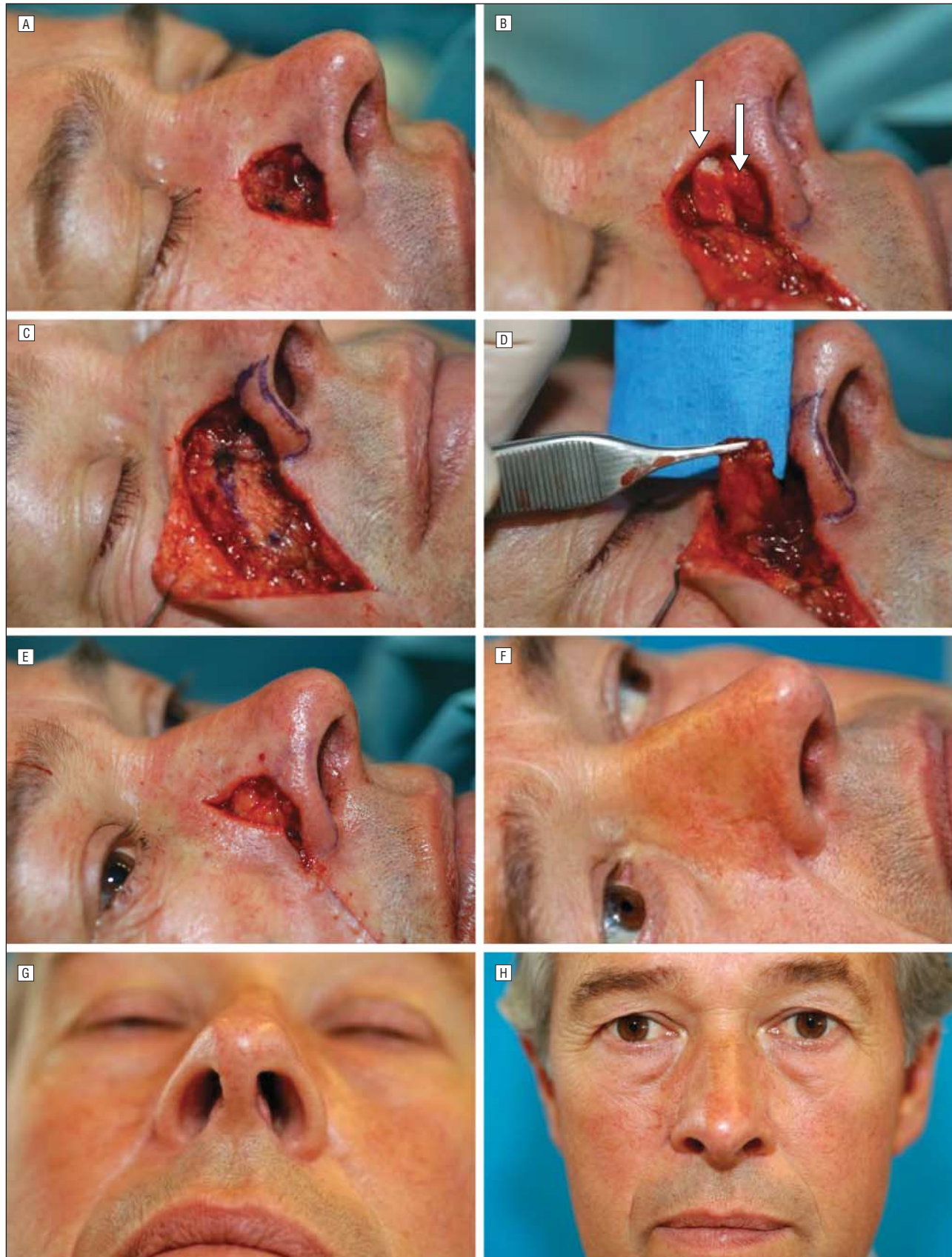
series reporting the use of this technique both used full-thickness skin grafts to cover the hinge flaps.<sup>3,5</sup>

We analyzed a series of 16 patients in whom reconstruction of Mohs surgery defects in the nasal area was successfully performed with a subcutaneous hinge flap, leaving it uncovered and allowing cutaneous healing to occur by secondary intention as suggested by Baker.<sup>4</sup>

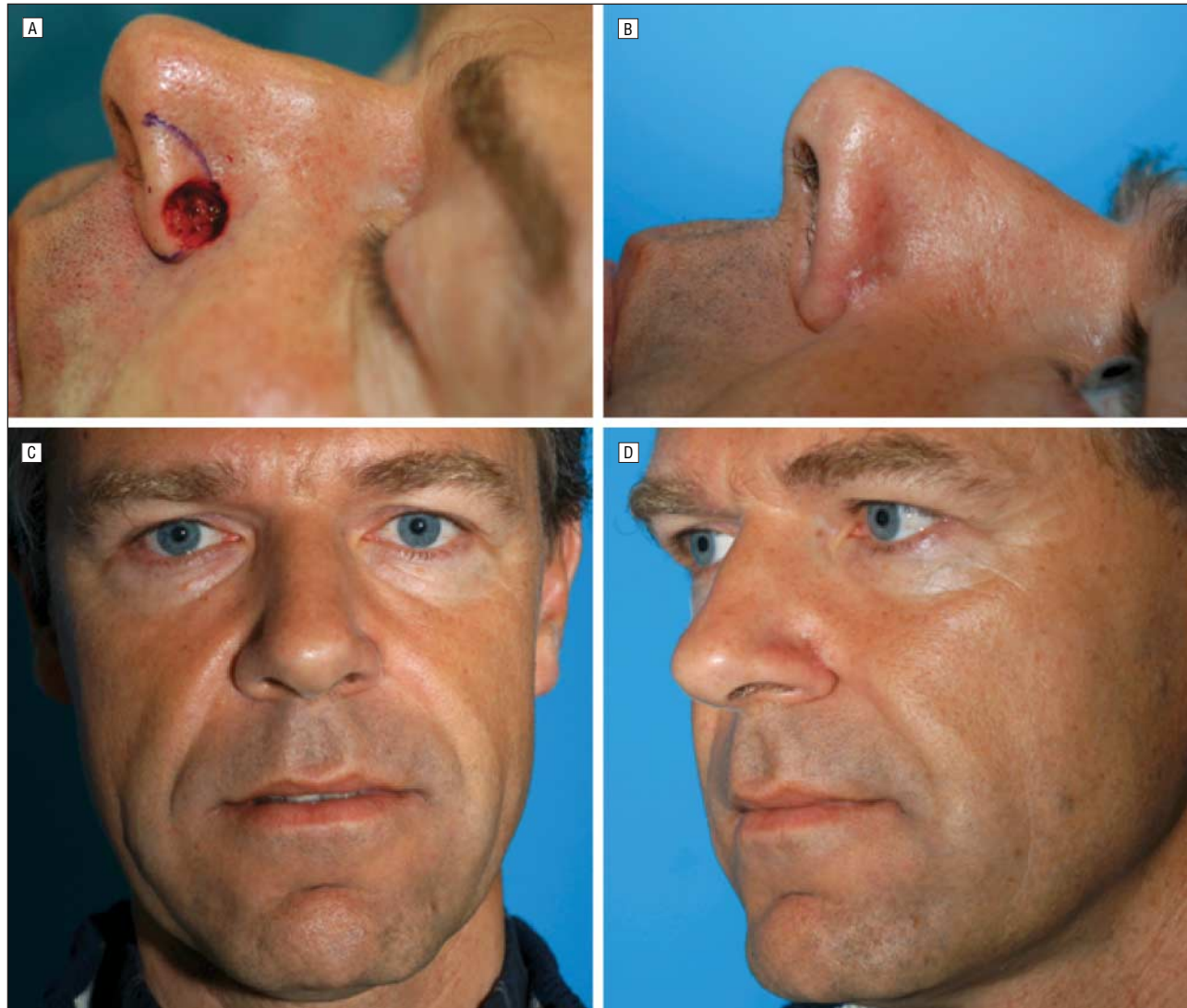## METHODS

This study included 9 women and 7 men (median age, 68 years; range, 44-79 years) with resection of nonmelanoma skin cancer (**Table**). The resulting defects all involved a portion of a subunit of the nose (sidewall or alar areas). Some involved the medial part of the cheek and, in addition, a portion of the top lip unit (**Figure 1**). The nasal defects were all relatively small (10-20 mm) but were often deep, although not involving nasal lining. Reconstruction was undertaken in a modular fashion, addressing each subunit individually. Typically, all nasal defects were reconstructed with an uncovered subcutaneous hinge flap, and the cheek defects were repaired with a medial cheek advancement flap.

The size and depth of the nasal defect was first assessed (**Figure 2A**). Autogenous free ear cartilage grafting was undertaken to replace any resected cartilage and to give support in a nonanatomic fashion for the alar rim and nasal valve (**Figure 2B**, arrows). A skin incision made lateral to the defect in the melolabial crease allowed undermining of the cheek to raise a skin flap (**Figure 2C**). The subcutaneous tissue was exposed and a hinge flap was marked out lateral to the defect. The subcutaneous fat flap was raised from lateral to medial, leaving the pedicle intact in the nasofacial sulcus area on which the flap was hinged into the deep nasal defect, similar to turning over a page in a book (**Figure 2D**). The flap was raised at a depth estimated to fill most of the resulting nasal defect after the cartilage grafting, while leaving an adequate pedicle thickness for vascular supply. The skin surrounding the original defect was undermined to allow the fat flap to be tucked in under the margin on all sides. A number of absorbable tacking sutures were placed between the surrounding skin of the nose and the superficial surface of the fat flap to help smooth the



**Figure 2.** Reconstruction of the nasal defect in patient 3. A, Original defect, mainly of the nasal sidewall. B, Two pieces of autogenous cartilage (arrows) are placed in the defect to give support, in a nonanatomic fashion, to the alar rim and nasal valve. C, A skin incision is made in the nasofacial groove above and in the melolabial crease below the defect. D, The subcutaneous hinge flap. E, Subcutaneous hinge flap is in position and the remaining defect is left to secondary-intention healing. F, Postoperatively, the cheek skin extends onto the nasal sidewall, with some minor effacement of the nasofacial groove. G and H, Additional postoperative views.



**Figure 3.** Aesthetic result of reconstruction of a lesion mainly on the alar subunit in patient 4.

contour between these areas and avoid any depressions after reepithelialization. Subsequently, the cheek skin was advanced medially in the standard manner to specifically repair the cheek portion of the wound (Figure 2E). Up to this point, part of the bare fat flap had been covered with the cheek flap as well. Care was taken when anchoring the cheek flap at the nasofacial groove area not to compromise the vascularity of the hinge flap's pedicle. The subcutaneous tissue flap was dressed with fusidic acid ointment and allowed to heal by secondary intention. Figures 2F, 2G, and 2H show the postoperative appearance.

We illustrate the technique with the following 2 typical cases.

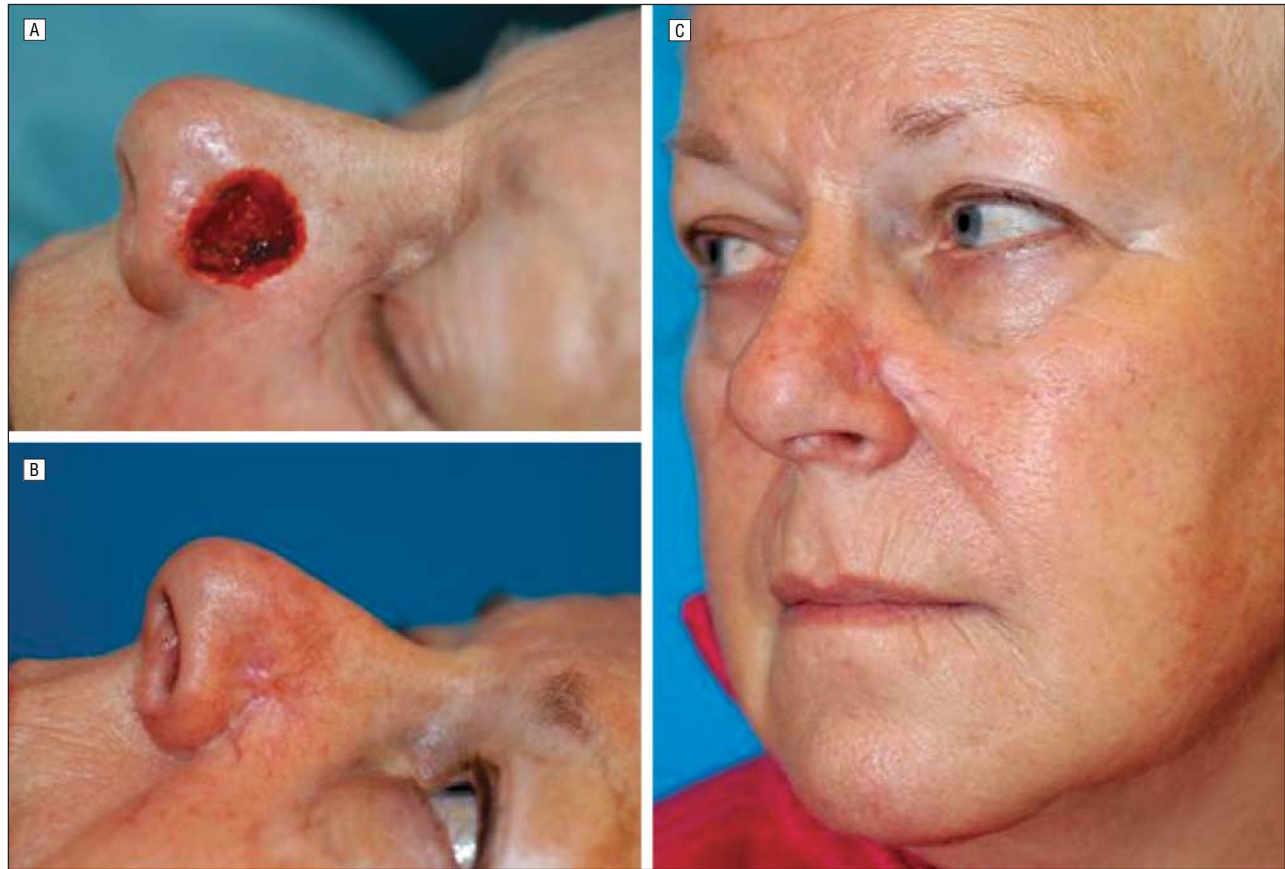
#### CASE 1

A 54-year-old man (patient 3 in the Table) presented with a recurrent basal cell carcinoma of the left side of the nose. Mohs excision was undertaken to ensure full tumor clearance. Of the resulting defect, 20% involved the nasal alar subunit, leaving the alar rim intact at a height of 3 to 4 mm (this was 40% of the alar subunit), 50% involved the nasal side wall, and the remaining 30% involved the medial part of the cheek (Figure 2). Reconstruction was undertaken with the use of autogenous conchal cartilage covered by a subcutaneous hinge flap. The cheek

defect was repaired with a cheek advancement flap, and the exposed fat flap allowed healing by secondary intention. Full epithelialization was seen at 4 weeks. The patient was entirely satisfied with the cosmetic effect of the repair and was unavailable for follow-up after 17 months.

#### CASE 2

A healthy 44-year-old man (patient 4 in the Table and **Figure 3**) presented with a primary basal cell carcinoma of the left side of the nose. After Mohs excision, 80% of the defect involved the alar subunit and 20% involved the lateral nasal wall. The depth of the defect was approximately 3 to 4 mm. Because the defect was less than 5 mm from the free alar margin, an autogenous cartilage graft was taken from the cymba conchae auriculae and positioned in the alar subunit while filling the defect. In this way, contraction of the alar rim was prevented and a good contour of the ala was achieved. The cartilage was covered with a subcutaneous hinge flap and left to heal by secondary intention. To preserve the supra-alar groove, no cheek advancement was used. The patient and the physician were satisfied with the result after 7 months. There was still some redness of the scar, but this was expected to improve over time.



**Figure 4.** Result of reconstruction of a large lesion mainly of the alar subunit and nasal side wall in a diabetic patient (patient 12). A, Preoperative view of the lesion. B and C, Postoperatively, a hypertrophic scar developed.

## RESULTS

In all 16 cases there was successful reepithelialization by secondary intention. This was normally complete by 4 to 6 weeks. Both patients and physicians assessed the results as either good or satisfactory. Follow-up in these patients ranged from 5 to 65 months, with a mean of 20 months.

A suboptimal cosmetic result was seen in patient 12 (**Figure 4**). This 63-year-old diabetic woman presented with a primary basal cell carcinoma of the lateral part of the nose. After Mohs excision, 80% of the defect was on the nasal sidewall, 10% on the medial cheek, and 10% on the alar subunit. Reconstruction involved only autogenous cartilage grafting and subcutaneous fat hinge flap. The adjacent cheek skin was elevated only to allow the hinge flap to be raised. The cheek skin was then replaced in the same position. Healing by secondary intention was allowed. At 13 months of follow-up, the patient still had a hypertrophic scar. Although the result was considered good, some degree of dissatisfaction remained because of the scar formation.

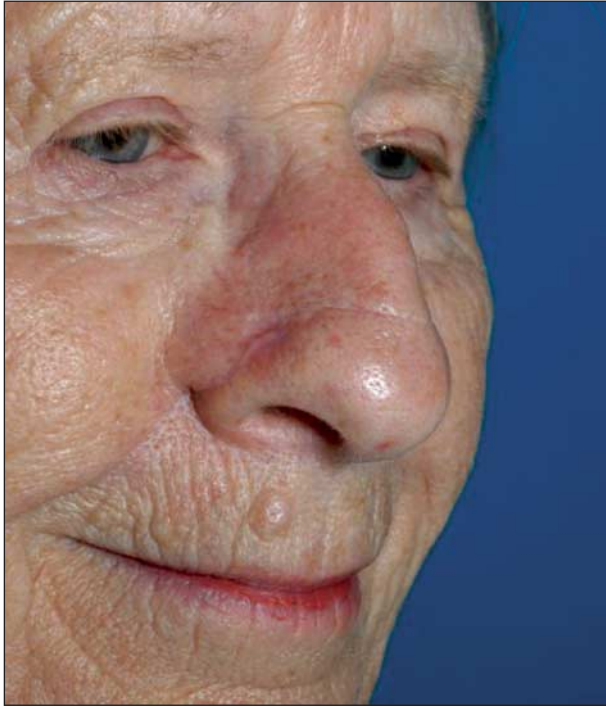
In total, 4 patients had minor cosmetic problems. In 1 patient (from early in the series) the underlying cartilage graft was prominent because of overretraction, and a minor revision was undertaken. One patient had obvious effacement of the nasofacial sulcus, possibly due to placement of cheek tissue onto the nasal side wall. One

patient developed a hypertrophic scar (**Figure 4B**), and 1 patient had effacement and hypertrophic scar formation together (**Figure 5**; patient 14). In the latter patient, cheek tissue that was brought medially contributed to the effacement of the nasofacial sulcus. None of these patients had considered revision at last follow-up.

## COMMENT

Reconstruction of defects in the region of the supra-alar groove poses particular problems. Various aesthetic units and subunits are contiguous in this area, and the contours of the tissues change abruptly between them. Reconstructions involving single pieces of tissue spanning these borders can efface the natural sulci and look both unnatural and unaesthetic. Consequently, it has become common practice to reconstruct defects spanning such boundaries in a modular fashion, addressing the portion of the defect in each aesthetic unit separately. This maintains the natural sulci and allows camouflage of suture lines in the natural borders of light and shade seen between different units and subunits. Generally this makes for a more pleasing cosmetic end result.

In lesions of the lower and lateral parts of the nose, a single defect may encroach on more than 1 subunit and so require a number of reconstructive techniques to be undertaken in a small anatomic area. These defects are often also quite deep. In addition to the surface cover-



**Figure 5.** Effacement of the nasofacial groove and hypertrophic scar formation in patient 14.

ing, it is vital to consider the structure and function of the underlying cartilage, which may be very superficial and may be involved with the resection. As well as playing a part in the contour of the nasal tip, the cartilage gives structural support to the nasal valve and provides structure to the nasal alar margin to resist retraction. The necessity for nonanatomic cartilage grafting in reconstructions of this area has previously been well documented.<sup>1,2</sup> The need for free cartilage grafts in this area excludes the use of free skin grafts alone and necessitates the use of a vascularized cartilage covering.

A lesion of the nasal alar subunit can be traditionally reconstructed by means of a melolabial flap. This can be accomplished as either an interpolated or a transposition flap. An interpolated melolabial flap will be wide enough only to replace alar tissue alone and would not be of use in situations where there is a concomitant nasal sidewall or cheek defect. In addition, where lesions extend into the cheek, an interpolated melolabial flap may be impossible because its pedicle will be disrupted by the cheek advancement flap necessary to reconstruct the cheek portion of the defect. A second-stage procedure is necessary to divide the flap's pedicle if an interpolated flap is used. In contrast, if a melolabial flap is used as a local transposition flap, no second stage is necessary and a larger area of tissue can be reconstructed, but this technique may blunt the nasofacial sulcus and the result may be unaesthetic. Another possibility for larger defects of the alar area is a forehead flap. This procedure requires the use of at least 2 stages and will result in a forehead scar, albeit negligible. Many patients and surgeons believe that this technique may cause unnecessary morbidity for the repair of a defect often measuring 10 to 20 mm in diameter.

Subcutaneous hinge flaps were described by Baker<sup>4</sup> more than 10 years ago, but the literature regarding them is sparse. They are proposed to be a useful option where there is a small but deep lesion of the lower or lateral part of the nose in conjunction with a contiguous cheek defect. The subcutaneous hinge flap is used to repair the nasal portion of the defect, and cheek advancement is easily performed to address the cheek portion. It has been suggested that the hinge flaps may be either covered with full-thickness skin grafts or left open to heal by secondary intention. Two series have been published previously showing good results with the subcutaneous flaps covered with skin grafts.<sup>3,5</sup>

In our series of 16 cases reconstructed with uncovered subcutaneous hinged fat flaps, the areas healed well by secondary intention in all patients. There were no cases of infection or flap failure. Most of the patients were satisfied with the end cosmetic effect of their treatment, and only 1 needed revision surgery. However, 3 types of aesthetic problems were delineated. To prevent effacement of the nasofacial groove, it is important to take the cheek advancement up to, but not over, the nasofacial groove area. Furthermore, the risk of effacement is decreased if the pedicle is not too thick and the hinge point is placed medially enough. To prevent hypertrophic scarring, reconstruction of a large defect may be facilitated by the combination of the subcutaneous hinge flap and a skin graft. Obviously, cartilage grafts need to be placed meticulously to prevent visible edges.

Our results indicate that the technique of uncovered subcutaneous hinge flaps is a simple, useful, 1-stage method of reconstructing small but deep defects involving the lower part of the nose and medial cheek area.

**Accepted for Publication:** July 12, 2007.

**Correspondence:** Paul van der Eerden, MD, Department of Otolaryngology, Lange Land Hospital, Toneellaan 1, 2725 KJ Zoetermeer, the Netherlands (P.vandereerden@llz.nl).

**Author Contributions:** *Study concept and design:* van der Eerden, Simmons, and Vuyk. *Acquisition of data:* van der Eerden and Vuyk. *Analysis and interpretation of data:* van der Eerden. *Drafting of the manuscript:* van der Eerden and Simmons. *Critical revision of the manuscript for important intellectual content:* van der Eerden, Simmons, and Vuyk. *Administrative, technical, and material support:* van der Eerden and Simmons. *Study supervision:* Vuyk.

**Financial Disclosure:** None reported.

## REFERENCES

1. Robinson JK, Burget GC. Nasal valve malfunction resulting from resection of cancer. *Arch Otolaryngol Head Neck Surg.* 1990;116(12):1419-1424.
2. Burget GC. Aesthetic reconstruction of the tip of the nose. *Dermatol Surg.* 1995; 21(5):419-429.
3. Johnson TM, Baker S, Brown MD, Nelson BR. Utility of the subcutaneous hinge flap in nasal reconstruction. *J Am Acad Dermatol.* 1994;30(3):459-466.
4. Baker SR. *Principles of Nasal Reconstruction.* St Louis, MO: Mosby; 2002:144-153.
5. Fader DJ, Wang TS, Johnson TM. Nasal reconstruction utilizing a muscle hinge flap with overlying full-thickness skin graft. *J Am Acad Dermatol.* 2000;43(5, pt 1):837-840.