

# Reconstruction of Dorsal and/or Caudal Nasal Septum Deformities With Septal Battens or by Septal Replacement: An Overview and Comparison of Techniques

Robert F. André, MD; Hadé D. Vuyk, MD, PhD

**Objectives:** The objectives of this study were to describe and compare two techniques used to correct nasal septum deviations located in the dorsal and/or caudal septum. **Study Design:** The authors conducted a retrospective clinical chart review. **Methods:** The authors conducted a comparison of functional and technical results between surgery in the L-strut of the septum in 114 patients with septal battens or by septal replacement by subjective self-evaluation and by examination of the position of the septum during follow up. **Results:** There was subjective improvement in nasal breathing in 86% of the septal batten group and in 94% of the septal replacement group. This difference was not statistically significant. The technical result was judged by examining the position of the septum during follow up as midline, slightly deviated, or severely deviated. The septum was significantly more often located in the midline during follow up in the septal replacement group than in the septal batten group. **Conclusion:** Treatment of deformities located in the structurally important L-strut of the septum may be technically challenging and many functional, structural, and esthetic considerations must be taken into account. On the basis of this series, both septal battens and septal replacement techniques may be considered for correction of deviations in this area. The functional improvement rates were not significantly different between the techniques, although during follow up, the septum appeared to be significantly more often located in the midline in the septal replacement group. The techniques are described and their respective advantages and potential drawbacks are dis-

cussed. **Key Words:** Nasal septum, L-strut, surgery, septal battens, septal replacement.

*Laryngoscope*, 116:1668–1673, 2006

## INTRODUCTION

As a result of its central role in the anatomy of the nose, a deformity in the nasal septum often has obvious consequences both for the nasal airway and the external aspect of the nose. Many variables may play a role in the outcome of septal surgery. Partly this is the result of the fact that it may be difficult to assess the exact influence of septal deformities on nasal patency, as other factors such as mucosal swelling and in- and external nasal valve pathology may contribute to nasal obstruction.<sup>1</sup> Furthermore, despite developments in rhinomanometry and acoustic rhinometry, we still lack uniform, clinically relevant, and reproducible objective tests for measuring nasal patency.<sup>2–4</sup> Although the extent of surgical manipulation largely determines the degree of possible correction, this may have consequence for the stability and shape of nasal structures.<sup>5,6</sup> In cases in which the dorsal or caudal parts of the septum are not involved, relatively straightforward septoplasty techniques may be successful in improving nasal breathing. As long as an L-shaped dorsal and caudal area of at least 1 cm is left intact, the entire underlying cartilaginous and bony septum may be repositioned and remodeled without structurally compromising or externally changing the nose.<sup>7</sup>

The situation becomes more complicated, however, when deviations or other deformities are located along the dorsal or caudal borders of the septum. The dorsal part of the cartilaginous septum is responsible for the anterior projection of the middle third of the nose, and deviations in this area are likely to be externally visible as asymmetries and/or deviation from the facial midline. Because of the connection of the dorsal part of the septum to the perpendicular plate of the ethmoid as well as to the upper lateral cartilages, surgical procedures in this area may affect the entire middle vault. This includes the function of the internal nasal valves, which are located at the angle

This study was presented at the annual meeting of the European Academy of Facial Plastic Surgery, September 30, 2005, Florence, Italy.

From the Department of Otolaryngology/Facial Plastic Surgery (R.F.A.), Rijnland Hospital, Leiderdorp, The Netherlands; and the Department of Otolaryngology/Facial Reconstructive Surgery (H.D.V.), Gooi Noord Hospital, Blaricum, The Netherlands.

Editor's Note: This Manuscript was accepted for publication June 5, 2006.

Send Correspondence to Dr. Robert F. André, Department of Otolaryngology/Facial Plastic Surgery, Rijnland Hospital, Simon Smitweg 1, 2353 GA Leiderdorp, The Netherlands. E-mail: r.andre@rijnland.nl.

DOI: 10.1097/01.mlg.0000233249.81424.20

between the septum and the lower border of the upper lateral cartilages. Because the attachment between the upper lateral cartilages and the septum may exert tension on a repositioned septum, it is frequently necessary to sever this connection to obtain a tension-free midline septal position. This in turn may cause internal nasal valve collapse if preventive measures such as the placement of spreader grafts are not taken.<sup>8-10</sup> A second important connection that is to be respected or restored to prevent postoperative loss of stability is found at the Keystone area where the cartilaginous septum and upper lateral cartilages are attached to the bony septum and nasal bones. The caudal part of the septum is intimately related to the premaxilla and anterior nasal spine and plays an important role in supporting the nasal tip both directly and through its connections to the lower lateral cartilages. These connections must be respected or restored if unwanted changes in the nasal tip are to be avoided after surgery. Irregularities in this portion of the septum may cause columellar deformities and/or asymmetric nostrils with possible external nasal valve collapse.<sup>11</sup>

It may be clear from this that any surgery performed in the dorsal or caudal portion of the septum may have many structural, functional, and esthetic consequences that need to be anticipated if satisfactory outcomes are to be achieved. Although the techniques that have been described for straightening septal cartilage in general can be applied to the dorsal and caudal septum, additional measures are necessary to maintain support and control the esthetic outcome. The various techniques currently in use, which incorporate the previously mentioned considerations, broadly fall into two categories. The first aims at straightening and/or repositioning the relevant parts of the septum by using techniques such as scoring, transecting, and thinning<sup>7,12</sup> and maintaining the changes made with subsequent use of sutures and/or bone or cartilage battens.<sup>13-17</sup> The second approach, referred to in this article as septal replacement, is to remove the affected part of the septum and then either replace it after external remodeling or replace it completely with an alternative material such as autogenous or banked rib cartilage or bone.<sup>18-26</sup> Both methods and their specific variations have frequently been described and can lead to good results but can be technically challenging and demand considerable experience to master. The varying success rates and descriptions we find in the literature are difficult to quantify or compare because many variables may play a role in individual patients and surgeons. A further difficulty in assessing the results of nasal surgery is the already mentioned lack of a uniform objective testing (and reporting) system; in other words, there will always be a certain subjective quality to statements regarding the effects of any given intervention.

## PATIENTS AND METHODS

To evaluate the relative value of each method, we retrospectively compared the results between the two techniques, carried out by the same surgeon, in two groups of patients as described subsequently. Although many of the reservations mentioned apply to our study as well, the amount of possible confounding factors was limited because the variables apart from the actual

procedure were very similar in each patient group (Table I). The main indication for surgery in each patient group was difficulty with nasal breathing caused, in part at least, by a dorsal and/or caudal septal deformity. Besides the functional problem, many patients also had cosmetic considerations that needed addressing. For the purposes of this study, the comparison of the results between the two groups only concerned the functional results as subjectively indicated by the patients and the technical results with respect to the postoperative position of the septum as judged by the surgeon during follow up.

Between 1995 and 2004, 154 patients with a deformity in the dorsal and/or caudal part of the septum were operated on by the senior author (H.D.V.) and underwent septal reconstruction either with septal battens or by means of septal replacement. After exclusion of patients with a follow up of less than 3 months, a history of cleft lip, or for whom insufficient data for analysis was available, 114 patients remained for evaluation. There were 76 men and 38 women and the average age was 32 years. The average follow up was 17 months (range, 3-129 months). Forty-nine patients (42%) only had functional complaints of difficulty with nasal breathing, whereas 65 patients (58%) had both functional and cosmetic reasons for seeking surgery. There were 69 patients in the septal batten group and 45 patients in the septal replacement group. In a majority of patients, in both groups, concomitant procedures aimed at improving nasal patency such as turbinate reductions, spreader graft placement and ethmoidectomies were done. Those procedures are likely to have influenced the outcomes in absolute terms, but because they were carried out in comparable numbers in both groups, a reasonable comparison between the two groups could still be made.

## Description of Technique

Either an endonasal or an open approach can be used for either technique, although, because of the superior exposition, an open approach is especially helpful for septal replacement.

**Septal Battens.** A variety of techniques are available for straightening and/or repositioning septal cartilage. In most cases, after elevation of bilateral mucoperichondrial flaps from the septum, the cartilaginous septum is first freed from its attachment to the premaxilla and in a majority of cases, a posterior chondrotomy between the cartilaginous and bony septum is made, like in a classic septoplasty. Where necessary basal and/or posterior strips of cartilage are resected, always leaving at least 1 cm of the dorsal and caudal L-strut intact. Any remaining deviations in the caudal or dorsal part of the septum can then be addressed. The main methods by which this is done involves either scoring or thinning of the cartilage on the concave side of the deformity or by a series of complete cuts through the cartilage. Both methods can result in cartilage moving from a curved to a straight plane. Next, septal battens are cut and shaped from excess septal cartilage, when available, otherwise from ear cartilage or from perpendicular plate bone. To maintain the straightening achieved, and also for structural support, the battens are then sutured to the septum (Fig. 1). In patients in whom the battens need to be positioned at the apex of the dorsal septum, because the deviation had extended all the way there, they take on a second function as spreader grafts. After addressing a caudal deformity, a caudal batten (or strut) is sutured to the septum. The caudal septum and batten are then fixated to the periosteum of the anterior nasal spine and usually also to the medial crura of the lower lateral cartilages in a tongue-in-groove fashion. Apart from correcting caudal deformities, the main purpose of a caudal strut is to support the nasal tip, but by adjusting the size and shape of the caudal batten and the fixation points to the medial crura, the projection and rotation of the nasal tip and the amount of columellar shown can be greatly influenced.<sup>27</sup> At the end of the

TABLE I.  
The Distribution of Variables in Each Patient Group.\*

Technique	No. of Patients	Average Age (years)	Sex	Sides Affected	Location of Deformity	Additional Procedures	Batten/Replacement Material	Previous Nasal Surgery	History of Trauma	Approach
Septal batten	69	32.8	64% male	26% unilateral	77% caudal	62% turbinate outfracture	65% septal cartilage	68%	23%	65% external
			36% female	74% bilateral	3% dorsal	60% ethmoidectomy	7% ear cartilage			35% closed
				20% both	57% spreader grafts	11% bone	0% rib			
Septal replacement	45	32.6	71% male	29% unilateral	74% caudal	77% turbinate outfracture	55% septal cartilage	86%	22%	93% external
			29% female	71% bilateral	2% dorsal	71% ethmoidectomy	2% ear cartilage			7% closed
				24% both	46% spreader grafts	5% bone	22% rib			
					5% none	16% combination				

\*Apart from the fact that (autogenous) rib cartilage was only used in the replacement group, and that there were more revision cases and more external approaches in the replacement group, the other variables were evenly distributed in both groups.

operation, quilting sutures are placed through the redraped mucosal layers and septum, and the marginal and columellar or hemitransfixion incisions are closed.

**Septal Replacement.** Septal replacement first involves the removal of the affected part of the cartilaginous septum after freeing it from all attachments holding it in place. More specifically, after dividing the connection with the upper lateral cartilages, developing complete submucoperichondrial tunnels on each side of the septum, separating the basal fibrous connections to the maxillary crest, and severing the posterior connection to the vomer and perpendicular plate of the ethmoid, the deformed part of the septum is lifted out of the nose. Depending on the situation, the septum can then either be remodeled externally were necessary making use of added autogenous ear or rib cartilage or bone or more rarely replaced completely with rib cartilage. The most critical factor when deciding which option to choose when replacing a newly formed septum is the availability of a sufficiently large, robust, and straight piece of cartilage for the L-shaped dorsal and caudal area (Fig. 2A). Sometimes such a piece can be formed by turning the septum upside down and using the basal part of the septum as a new dorsum. Often, however, mainly because of concomitant basal deformities, this alone will not solve the problem and added cartilage or bone is necessary to build a new septum. Although not used in this series, recent experience using PDS foil as a template when reconstructing the septum has proved useful.<sup>28</sup> Irrespective of the material used, the replaced cartilage must be securely fixated in position (Fig. 2B). Posteriorly, it is sutured to the bony septum or nasal bones through a burr hole. Caudally, it is held in place by sutures through the periosteum of, or a burr hole through, the anterior nasal spine. Placing the septum in a predrilled groove in the premaxilla gives additional support and reduces the chance of (late) postoperative deformities<sup>20</sup> (Fig. 3). The upper lateral cartilages are reattached to the septum, where necessary, separated by spreader grafts (Fig. 4A), and the caudal cartilage is contoured and sutured to the medial crura (Fig. 4B). A key feature of the technique described is that only the deformed part and the entire septum is not removed. By leaving as much of the nondeformed septum intact as possible, a minimum amount of destabilization occurs, and furthermore, the replaced septum can be securely fixated to the remnants of the original septum.

## RESULTS

In the septal batten group, there were 69 patients with functional complaints on 120 sides (18 unilateral, 51 bilateral). Postoperatively, 63% of sides were rated as optimal and 23% as improved. Twelve percent were equal and on two sides (approximately 2%); the postoperative situation was worse. In the septal replacement group, there were 45 patients with obstructed airflow on 77 sides (13 unilateral, 32 bilateral). Postoperatively, on 69% of sides, the patients rated their nasal breathing as optimal and on 25% as improved. In 5%, no change was noted, and on one side (approximately 1%), it was worse. So in the septal replacement group, the overall improvement rate was 94% compared with 86% in the septal batten group. Statistical analysis using Pearson  $\chi^2$  crosstabulation tests, both for the unilateral and for the bilateral cases, were carried out. The differences in outcome between the two groups did not reach statistical significance ( $P = .634$  for the unilateral cases and  $P = .092$  for the bilateral cases).

The technical result was rated during follow up by judging the position of the septum as midline, slightly deviated, or severely deviated. In the septal batten group,

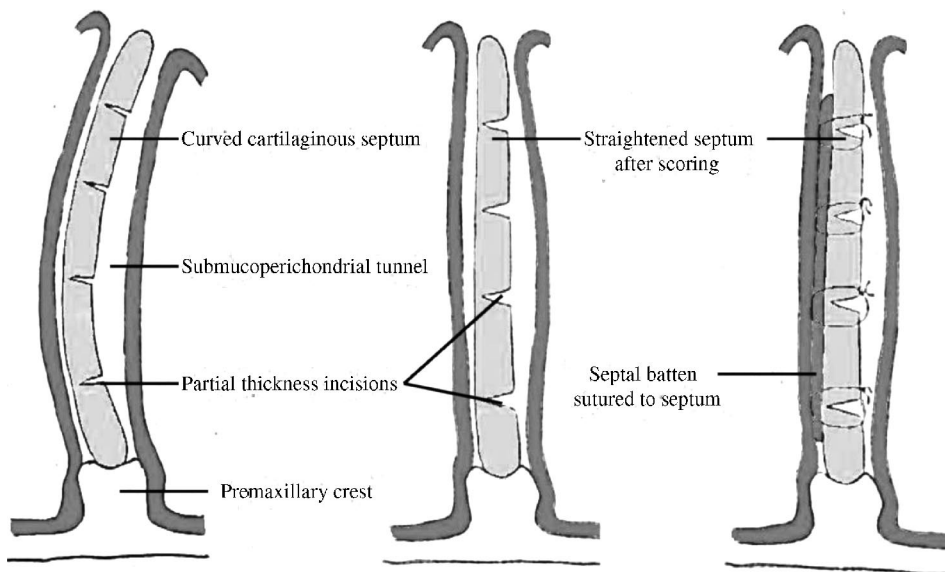


Fig. 1. Schematic drawing of the principle of septal batten. In this example, the septum is straightened by scoring the cartilage on the concave side of the deviation after which a batten is sutured to the septum to prevent a recurrent deviation.

54% of septums were midline, 44% slightly deviated, and 2% severely deviated. In some patients, the septum was visibly widened because of the batten. In the septal replacement group, 75% of septums were midline and 25% slightly deviated without any obvious septal thickening.

This difference in favor of the septal replacement group did reach statistical significance after Pearson  $\chi^2$  cross-tabulation analysis ( $P = .018$ ).

#### DISCUSSION

Modern septal surgery has developed along the same lines as rhinoplasty. In modern rhinoplasty, emphasis is now more on conservation, repositioning, and restructuring rather than on resection. Ideally, any surgical step can be incrementally applied and is reversible. To a large extent, batten grafting conforms to these prerequisites more than septal replacement, which involves more resection and destabilization. In the comparison we made, both from a functional and from a technical point of view (indicated by the position of the septum during follow up),

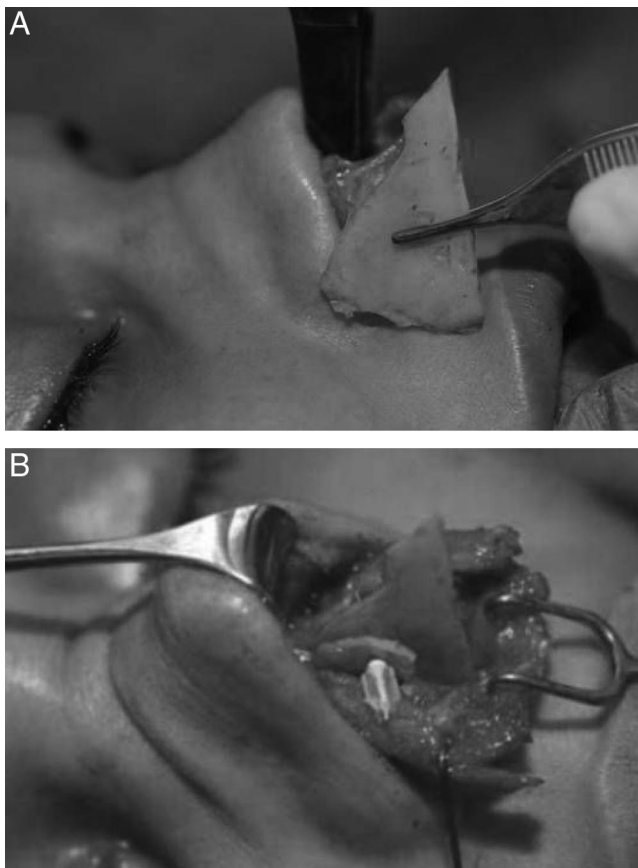


Fig. 2. (A and B) A large and straight piece of cartilage harvested from the posterior septum can serve as basis for the new dorsal area of the reconstructed septum.

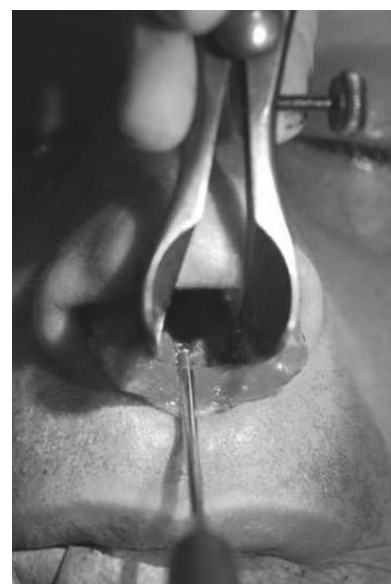

Fig. 3. A groove may be drilled in the premaxilla in which the new septum can be positioned for extra support and stability.

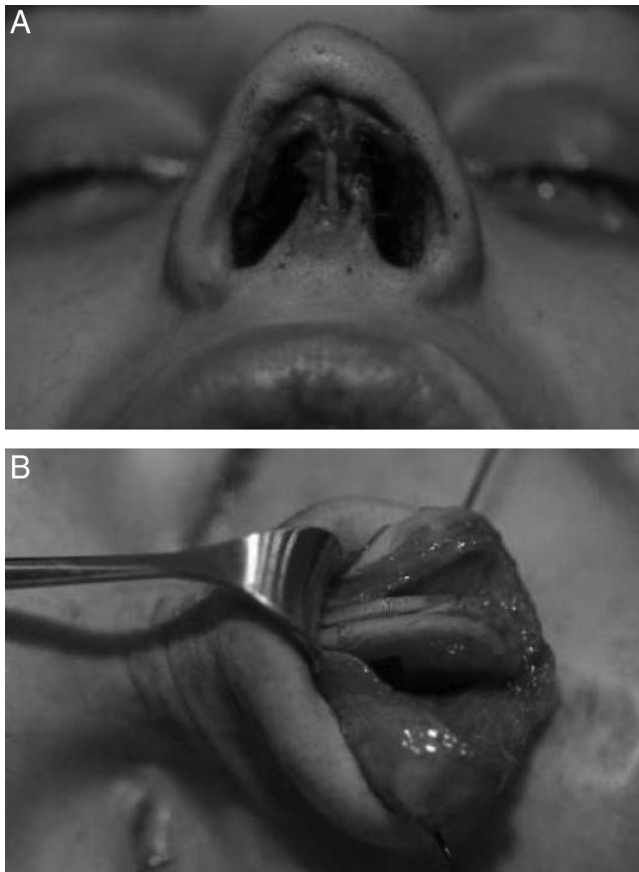


Fig. 4. (A and B) The upper lateral cartilages are reattached to the septum, usually separated by spreader grafts, and the caudal cartilage is contoured, where necessary augmented with a caudal strut, and sutured to the medial crura.

the results appeared better in the septal replacement group, although the functional differences did not reach statistical significance. When judging the postoperative position of the septum, it was (significantly) more often located in the midline in the septal replacement group than in the septal batten group. This might be explained by several circumstances. In the first place, it is easier to form a completely straight plane externally, on a side table, than while the septum is still in the nose. Such a newly formed septum can probably also be reinserted more accurately than a septum, which still has several attachments leaving less latitude for precise positioning. Furthermore, a septum that has been completely remodeled outside of the nose is probably less likely to contain residual inherent tensile forces or cartilage memory causing later distortion than a septum, which has been remodeled internally. Of course, the main purpose of septal battens is to counter those forces, but it is not hard to imagine that they might not always succeed in doing so during the healing process in the postoperative period. A further disadvantage of septal battens is that they always cause a certain extent of thickening, and in some cases, this may have a negative effect on nasal patency, especially in the caudal septum. A relative advantage of using battens is that the surgery is less invasive and generally less

time-consuming because fewer supporting structures need to be severed, thereby reducing the risk of postoperative loss of stability of the middle and lower third of the nose compared with septal replacement. This risk can, however, be minimized when the remodeled septum is meticulously fixated after reinsertion and was not an issue in this series.

## CONCLUSION

Septal surgery for caudal and/or dorsal deformities can be a complex undertaking because many considerations, concerning form, stability, and function of the nose, must be taken into account. This article describes and compares two techniques used to treat deformities of the L-shaped septal support structure. Both the use of septal battens and the technique of septal replacement may lead to good results because both respect or restore the structural integrity of the nose and each technique has its relative merits and disadvantages. On the basis of this series, we generally would advise (partial) septal replacement for the more pronounced cases because this is more likely to lead to a straight septum, especially when both the caudal and dorsal parts of the septum are involved. An isolated deformity can probably often be addressed with septal battens alone.

## Acknowledgments

The authors acknowledge Ron Wolterbeek of the Department of Medical Statistics of the Leiden University Medical Centre for the statistical analysis of the data.

## BIBLIOGRAPHY

1. Constantian MB, Clardy RB. The relative importance of septal and nasal valvular surgery in correcting airway obstruction in primary and secondary rhinoplasty. *Plast Reconstr Surg* 1996;98:38–54; discussion 55–58.
2. Panagou P, Loukides S, Tsipra S, Syrigou K, Anastakis C, Kalogeropoulos N. Evaluation of nasal patency: comparison of patient and clinician assessments with rhinomanometry. *Arch Otolaryngol* 1998;118:847–851.
3. Silkoff PE, Chakravorty S, Chapnik J, Cole P, Zamel N. Reproducibility of acoustic rhinometry and rhinomanometry in normal subjects. *Am J Rhinol* 1999;13:131–135.
4. Sipila J, Suonpaa J, Laippala P. Sensation of nasal obstruction compared to rhinomanometric results in patients referred for septoplasty. *Rhinology* 1994;32:141–144.
5. Guyuron B, Uzzo CD, Scull H. A practical classification of septonasal deviation and an effective guide to septal surgery. *Plast Reconstr Surg* 1999;104:2202–2209; discussion 2210–2212.
6. Vuyk HD. A review of practical guidelines for correction of the deviated, asymmetric nose. *Rhinology* 2000;38:72–78.
7. Gunter JP, Rohrich RJ. Management of the deviated nose. The importance of septal reconstruction. *Clin Plast Surg* 1988;15:43–55.
8. Sheen JH. Spreader graft: a method of reconstructing the roof of the middle nasal vault following rhinoplasty. *Plast Reconstr Surg* 1984;73:230–239.
9. Rohrich RJ, Hollier LH. Use of spreader grafts in the external approach to rhinoplasty. *Clin Plast Surg* 1996;23:255–262.
10. André RF, Paun SH, Vuyk HD. Endonasal spreader graft placement as treatment for internal nasal valve insufficiency: no need to divide the upper lateral cartilages from the septum. *Arch Facial Plast Surg* 2004;6:36–40.
11. Guyuron B, Behmand RA. Caudal nasal deviation. *Plast Reconstr Surg* 2003;111:2449–2457; discussion 2458–2459.

12. Murakami WT, Wong LW, Davidson TM. Applications of the biomechanical behavior of cartilage to nasal septoplasty surgery. *Laryngoscope* 1982;92:300–309.
13. Dupont C, Cloutier GE, Prevost Y. Autogenous vomer bone graft for permanent correction of the cartilaginous septal deviations. *Plast Reconstr Surg* 1966;38:243–247.
14. Rettinger G. Aktuelle Aspekte der Septorhinoplastik. *Otorhinolaryngol Nova* 1992;2:70–79.
15. Metzinger SE, Boyce RG, Rigby PL, Joseph JJ, Anderson JR. Ethmoid bone sandwich grafting for caudal septal defects. *Arch Otolaryngol Head Neck Surg* 1994;120:1121–1125.
16. Ramirez OM, Pozner JN. The severely twisted nose. Treatment by separation of its components and internal cartilage splinting. *Clin Plast Surg* 1996;23:327–340.
17. Dyer WK, Kang J. Correction of severe caudal deflections with a cartilage ‘plating’ rigid fixation graft. *Arch Otolaryngol Head Neck Surg* 2000;126:973–978.
18. Rees TD. Surgical correction of the severely deviated nose by extramucosal excision of the osseocartilaginous septum and replacement as a free graft. *Plast Reconstr Surg* 1986;78:320–330.
19. Toriumi DM. Subtotal reconstruction of the nasal septum: a preliminary report. *Laryngoscope* 1994;104:906–913.
20. Gubisch W. The extracorporeal septum plasty: a technique to correct difficult nasal deformities. *Plast Reconstr Surg* 1995;95:672–682.
21. Gubisch W, Constantinescu MA. Refinements in extracorporeal septoplasty. *Plast Reconstr Surg* 1999;104:1131–1139; discussion 1140–1142.
22. Gubisch W. Extracorporeal septoplasty for the markedly deviated septum. *Arch Facial Plast Surg* 2005;7:218–226.
23. Senyuva C, Yucel A, Aydin Y, Okur I, Guzel Z. Extracorporeal septoplasty combined with open rhinoplasty. *Aesthetic Plast Surg* 1997;21:233–239.
24. Sciuto S, Bernardeschi D. Excision and replacement of nasal septum in aesthetic and functional nose surgery: setting criteria and establishing indications. *Rhinology* 1999;37:74–79.
25. Murrell GL, Requena R, Wall MP. Septal replacement for severe anterior septal deviation. *Am J Otolaryngol* 2000;21:147–152.
26. Pirsig W, Kern EB, Verse T. Reconstruction of anterior nasal septum: back-to-back autogenous ear cartilage graft. *Laryngoscope* 2004;114:627–638.
27. Kridel RW, Scott BA, Foda HM. The tongue-in-groove technique in septorhinoplasty. A 10-year experience. *Arch Facial Plast Surg* 1999;1:246–256; discussion 257–258.
28. Boenisch M, Mink A. Clinical and histological results of septoplasty with a resorbable implant. *Arch Otolaryngol Head Neck Surg* 2000;126:1373–1377.